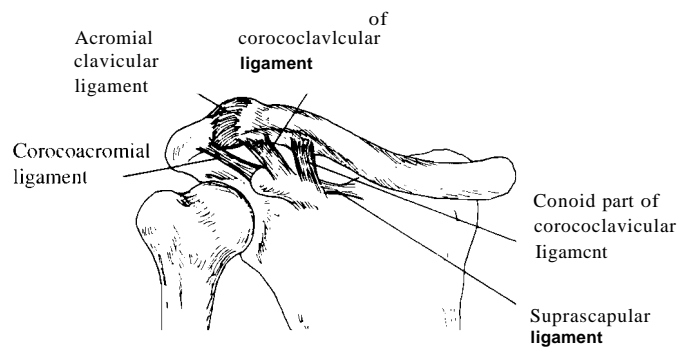


Acromioclavicular Joints

Innervation: Suprascapular and lateral pectoral nerves.

Arteries: Suprascapular and thoraco-acromial arteries.

Movements: (As associated with those of the scapula.) Elevation, depression, protraction, retraction, upward and downward rotation.



View: Anterior inferior

