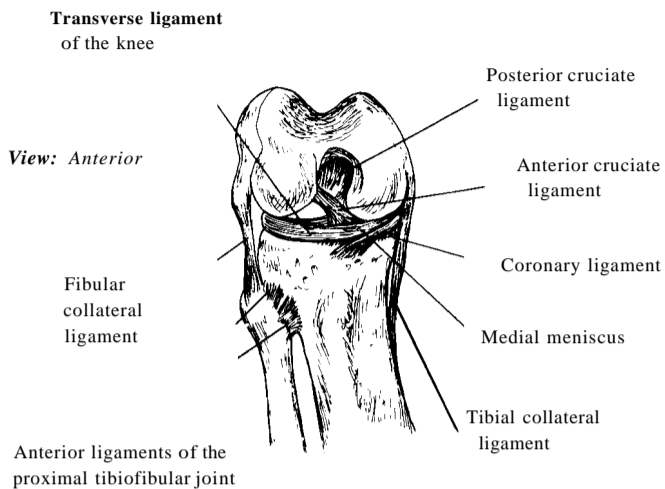


# Knee Joint

**Innervation:** Obturator, femoral, tibial and common peroneal nerves.

**Arteries:** Descending genicular branches of the femoral, superior, middle, and inferior genicular branches of the popliteal, descending branch of the lateral circumflex femoral, and the anterior and posterior recurrent branches of the anterior tibial.

**Movements:** Flexion - extension, medial and lateral rotation.



**Note:** The right knee is in full flexion.

