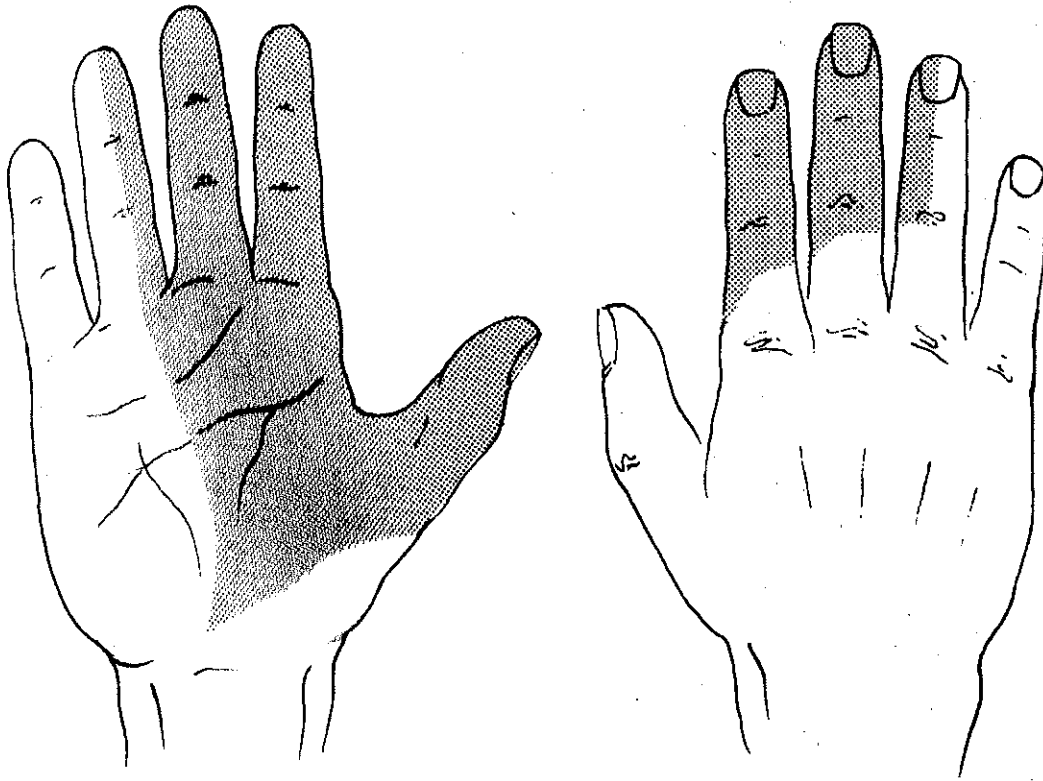


Figure 1 Sensory innervation of the hand



Shading indicates areas of median nerve innervation.

Figure 2 Motor innervation of the hand

