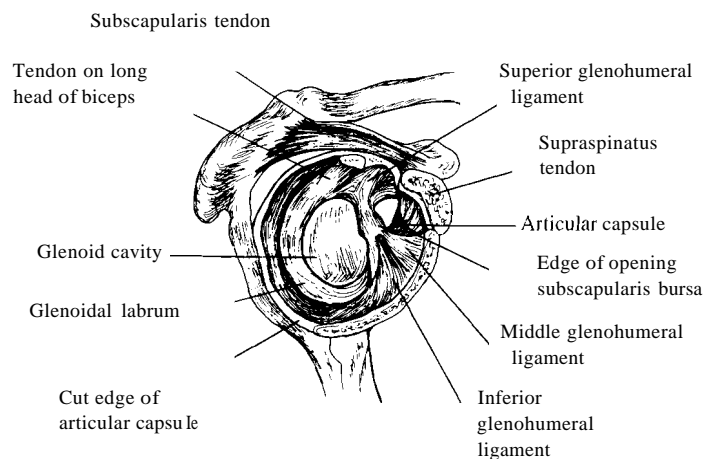


## Glenohumeral Joint (Shoulder Joint)

**Innervation:** Posterior cord of the brachial plexus and the suprascapular, axillary lateral nerves.

**Arteries:** Anterior and posterior circumflex humeral and suprascapular arteries.

**Movements:** Flexion - extension, abduction - adduction, circumduction, medial, and lateral rotation.



**View:** Anterolateral with head of humerus removed.

